Available online at www.journalijmrr.com

INTERNATIONAL JOURNAL OF MODERN RESEARCH AND REVIEWS

ISSN: 2347-8314

Int. J. Modn. Res. Revs.

Volume 2, Issue 10, pp 421-427, October, 2014

ORIGINAL ARTICLE

STUDY OF VARIOUS MODALITIES OF SURGICAL MANAGEMENT OF UNSTABLE INTERTROCHANTERIC FRACTURES

***[1]Dr. Madu Sridhar and [2]Dr. R. Neelakrishnan**

1Post Graduate, Department of Orthopaedics, Rajah Muthiah Medical College & Hospital, Annamalai University, Annamalainagar – 608 002, Tamil Nadu, India

2Professor, Department of Orthopaedics, Rajah Muthiah Medical College & Hospital, Annamalai University, Annamalainagar – 608 002, Tamil Nadu, India

Article History: *Received 5th September,2014, Accepted 6th October, 2014, Published 7th October,2014*

ABSTRACT

Introduction: Several fixation devices have been developed to overcome the difficulties encountered in the treatment of unstable intertrochanteric femoral fractures. However the management of such fractures still remains a point of discussion.
Aim of the Study: This study is undertaken to assess the various modalities of surgical management of unstable intertrochanteric fractures and their clinical, functional and radiological outcomes in our institution.**Materials and Methods:** This is a prospective study from July 2013 to March 2014. The study included 42 patients (Mean age – 56.21 years) who underwent various modalities of surgical management for unstable intertrochanteric fractures. Out of the 42 patients, 19 underwent Dynamic Hip Screw fixation, 12 underwent Proximal Femoral Nailing, 8 underwent Proximal Femur Locking Compression Plating and 3 underwent Dynamic Condylar Screw fixation. The results were assessed clinically and radiographically. Clinical evaluation was made using the Harris hip score. Perioperative complications were recorded. The mean follow-up period was 10.2 months (range 6 to 14 months).**Results:**Fracture union was achieved in all cases. Bony consolidation was seen after a mean of 15.05 weeks (range 12 to 22 weeks) and the time until full weight bearing ranged from 10 to 18 weeks. The mean Harris hip score was 85.02 (PFN – 88.25, DHS – 83, PFLCP – 86.25, DCS – 82). None of the patients had a poor Harris hip score. Superficial wound infection occurred in 3 patients and varus collapse in 4 patients. None of the patients had implant breakage or screw cut out or deep infection.**Conclusion:**Due to the quicker union time, earlier postoperative mobilization, shorter operation time and better functional outcome, PFN seems to have distinct advantages over the other implants and is currently the implant of choice in the surgical management of unstable intertrochanteric fractures. However, the DHS, PFLCP and DCS have their own set of advantages and indications and play a role in the management of certain specific fracture types.

Keywords: Unstable Intertrochanteric Fractures, Dynamic Hip Screw, Proximal Femur Nail, Dynamic Condylar Screw, Proximal Femur Locking Compression Plate, Harris Hip Score

1.INTRODUCTION

Intertrochanteric fracture is one of the most common fractures of the hip especially in the elderly with osteoporoticbones, usually due to low-energy trauma like simple falls. In the younger age group, where UnstableIntertrochanteric fractures are more common, the cause is usually a high-energy trauma like road trafficaccidents.The incidence of intertrochanteric fracture is rising because of increasing number of senior citizenswith osteoporosis and also the increasing number of road traffic accidents. In India the incidence is estimated to double by 2040. Problems of these fractures are (1) association with substantial morbidity and mortality (2) malunion (3) implant failure, cutout of head, and penetration into hip (4) great financial burden to the family (5) associated medical problem like diabetes, hypertension.

Unstable Intertrochanteric fractures are those where there is poor contact between fracture fragments, especially medial and posterior cortex displacement, comminution or a fracture pattern such that the weight bearing forces tend to displace the fracture further or a reverse oblique type.

The Factors most significant for instability and fixation failure in an Unstable intertrochanteric fracture are: (i) loss of posteromedial support, (ii) severe comminution, (iii) subtrochanteric extension of the fracture,(iv) reverse oblique fracture, (v) shattered lateral wall and (vi) extension into femoral neck area

**Corresponding* author *Dr. Madu Sridhar, Department of Orthopaedics, Rajah Muthiah Medical College & Hospital, Annamalai University, Annamalainagar – 608 002, Tamilnadu, India*

It is universally agreed that the treatment of unstable intertrochanteric fractures is stable internal fixation as early as possible since malunion and varusangulation are common if left untreated or treated improperly, leading to substantial morbidity. The demand on the patient, nursing staff and the length of hospitalization period render conservative method of treatment of such fractures unacceptable today.

Stable IT fractures are commonly treated with Dynamic hip screw (DHS) fixation with failure rates of lessthan 2%. The treatment of unstable IT fractures is more controversial. Unstable IT fractures treated with DHShave a considerably higher rate of failure, ranging from 4% to 15%. Other treatment modalities for unstable IT fractures include intramedullary devices, other extramedullary devices and hemiarthroplasty. However, despite many methods, there has been no gold-standard treatment for unstable fractures.

Results of randomised clinical studies comparing theresults of intramedullary or extramedullaryfixation or prosthetic replacement techniques for unstabletrochanteric fractures are inconsistent and rare. Most comparative studies focus on treatment of stable trochanteric fracture types.

This study was undertaken to assess the various modalities of internal fixation of unstableintertrochanteric fractures and their clinical, functional and radiological outcomes in our institution.

2.MATERIALS AND METHODS :

This was a prospective study conducted at RAJAH MUTHIAH MEDICAL COLLEGE AND HOSPITAL, ANNAMALAI UNIVERSITY from July 2013 to March 2014. During this period 42 adult patients with unstable intertrochanteric fractures, classified according to the AO/OTA classification, were selected according to inclusion criteria.

Out of the 42 patients, 19 underwent Dynamic Hip Screw (DHS) fixation, 12 underwent Proximal Femur Nailing (PFN), 8 underwent fixation with Proximal Femur Locking Compression Plate (PFLCP) and 3 with Dynamic Condylar Screw (DCS). The choice of implant for each patient was based on the individual fracture geometry and age of the patient. It was a comparative study. The mean follow up period was 10.2 months (Range 6 – 14 months).

All the cases were followed up at regular intervals. In all the patients, along with personal data, mode of trauma, type of fracture, type of surgery, intra operative & postoperative complications, follow up examination including hip joint examination and duration of full weight bearing were considered. This study was conducted with due emphasis for analysis of functional and radiological outcome of surgical management of unstable intertrochanteric fractures.

Inclusion Criteria :

- Radiological diagnosis of an unstable intertrochanteric fracture, classified as 31A2.1 to 3 and 31A3.1 to 3 according to the AO/OTA classification of long bone fractures
- Age group 18 years to 70 years
- Injury less than 1 month old

Exclusion Criteria :

- Age below 18 years and above 70 years
- Stable intertrochanteric fracture
- Unstable Intertrochanteric fractures treated by prosthetic replacement
- Pathological fracture
- Open fracture
- Presence of infection
- Associated ipsilateral femoral shaft fractures
- Patients unfit for anaesthesia and major surgical intervention

On arrival, all the patients were haemodynamically stabilized following which they were subjected to radiographic evaluation with the following x-rays:

1. X ray Pelvis with both Hips AP view
2. AP view of the involved proximal femur with Traction and Internal rotation
3. AP and Lateral views of the involved femur with knee joint.

The fractures were classified based on the radiographs taken and management planned. The implants were chosen after taking into consideration the individual fracture morphology, age of the patient and associated co-morbidities. Following this the patients underwent routine investigations. . Pre-operative anaesthetic & physician fitness obtained. Pre-operative parenteral antibiotics[1]administered 1hr before surgery. Skin preparation done on the day of surgery.

Surgical Procedure:

The patient was positioned supine on the fracture table. Reduction was carried out by closed means whenever possible under image intensifier guidance. In cases where closed reduction did not yield satisfactory results, open reduction was done. In 8 out of 11 patients who underwent open reduction, Iliopsoas tendon release was done. After achieving satisfactory reduction, the fracture was stabilized with the chosen implant. A standard lateral approach was used for DHS/DCS/PFLCP. A small 3 cm incision proximal to the tip of greater trochanter was used for PFN. After the procedure, thorough wound wash was given and wound was closed in layers after inserting a drain.

Follow up & Evaluation:

Standard post operative protocol was followed and the patient was mobilized partial weight bearing with walker support at the end of 6 weeks. All patients were followed up every 2 weeks until 6 weeks followed by monthly follow up until 6 months. Radiologic outcome was evaluated by taking check X-Rays in the immediate post op period, at 6 weeks and at the end of 3 months and 6 months. Statistical analysis was made using the Chi-Square test. Functional outcome was evaluated using the Modified Harris Hip Score[2,3]at 3rd month and 6th month post operatively.

3.RESULTS

Fracture union was achieved in all cases. Bony consolidation was seen after a mean of 15.05 weeks (range 12 to 22 weeks) and the mean time until full weight bearing was 10 to

18 weeks. The mean Harris hip score was 85.02 (PFN – 88.25, DHS – 83, PFLCP – 86.25, DCS – 82). None of the patients had a poor Harris hip score. Superficial wound infection occurred in 3 patients and varus collapse in 4 patients. None of the patients had implant breakage or screw cut out or deep infection.

Table – 1: ASSOCIATION OF TIME OF UNION WITH TYPE OF FIXATION

TIME OF UNION (WEEKS)	NUMBER OF PATIENTS	PERCENTAGE
12.14	22	52.4
15.17	14	33.3
18.20	5	11.9
≥ 21	1	2.4
TOTAL	42	100

TIME OF UNION (WEEKS)	TYPE OF FIXATION							
	DHS		PFN		PFP		DCS	
	N	%	N	%	N	%	N	%
12-14	9	47.37	8	66.67	4	50	1	33.33
15-17	9	47.37	2	16.67	3	37.5	0	0
18-20	1	5.26	2	16.67	0	0	2	66.67
>20	0	.04	0	0	1	12.5	0	0
	19	100	12	100	8	100	3	100

	VALUE	'P'-Value
Chi – Square Test	17.632	.040

Table – 2: ASSOCIATION OF MODIFIED HARRIS HIP SCORE WITH TYPE OF FIXATION

MODIFIED HARRIS HIP SCORE	NUMBER OF PATIENTS	PERCENTAGE
>90 (EXCELLENT)	9	21.4
80-89 (GOOD)	24	57.1
70-79 (FAIR)	9	21.4
<70 (POOR)	0	0
TOTAL	42	100

	MEAN	STANDAND DEVIATION (S.D)
Modified Harris Hip Score	85.02	6.13

	FIXATION							
	DHS		PFN		PFP		DCS	
	N	%	N	%	N	%	N	%
>90	3	15.79	5	41.67	1	12.5	0	0
80-89	12	63.16	6	50	6	75	0	0
70-79	4	21.05	1	8.33	1	12.5	3	100
TOTAL	19	100	12	100	8	100	3	100

	VALUE	'P'-Value
Chi-Square Test	15.806	.015

Table -3: ASSOCIATION OF TYPE OF FIXATION AND COMPLICATION

POST OP COMPLICATION	NUMBER OF PATIENTS	PERCENTAGE
VARUS ANGULATION	4	9.5
SUPERFICIAL INFECTION	3	7.1
NIL	35	83.3
TOTAL	42	100

ILLUSTRATIVE CASES

Case 1 – 68/F, Right side, Type 31A2.2

Pre-OP

Immediate Post-OP

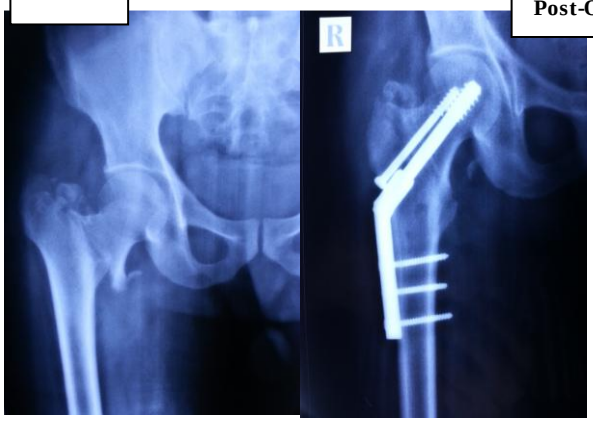

6 weeks Post OP

3 months post OP

Functional outcome at Six months

4.DISCUSSION:

Unstable intertrochanteric fractures of the femur have been recognized as a major challenge by the orthopaedic community, not solely for achieving fracture union, but for restoration of optimal function in the shortest possible time, that too with minimal complications. The aim of management is to achieve early mobilization, rapid rehabilitation and quick return of individuals to premorbid home and work environment as a functionally and psychologically independent unit.

In the elderly patient, conservative treatment leads to complications such as hypostatic pneumonia, decubitus ulcers, retention of urine and urinary tract infection, disuse osteoporosis, disuse atrophy of muscles, joint contracture and stiffness and deep vein thrombosis.

Operative treatment in the form of internal fixation permits early rehabilitation and offers the best chance of functional recovery, and hence has become the treatment of choice for virtually all fractures in the trochanteric region.

Amongst the various types of intramedullary and extramedullary implants available, the **Dynamic Hip Screw (DHS)** is most commonly used and still remains the "Gold Standard" for Stable intertrochanteric fractures. However, according to the study by Saarenpaa et al[4], Sliding Hip Screws used in the treatment of Unstable trochanteric fractures have a very high failure rate with a reoperation rate of 8.2 % which is unacceptable in the present day scenario.

Dynamic Condylar Screw (DCS) has traditionally been used in the treatment of Unstable proximal femoral fractures, especially those with a reverse obliquity pattern or extension into the lateral wall. However, various studies using this implant have yielded contradictory results. Haidukewych et al[5]noted that the Dynamic Condylar Screw perfomed significantly better than the Dynamic Hip Screw in their series of patients with reverse oblique type of unstable proximal femoral fractures. However, a similar study by Sadowskiet al[6]on similar fracture patterns showed an inferior outcome with these implants when compared with intramedullary nails.

Control of axial telescoping and rotational stability are essential in unstable proximal femoral fractures. An intramedullary implant inserted in a minimally invasive manner is better tolerated in the elderly patients[7]. The cephalomedullary nails with a trochanteric entry point have gained popularity in recent years[8] . They have been shown to be biomechanically [9]stronger than extramedullary implants. The Gamma nail is associated with specific complications, among which anterior thigh pain[10]and fracture of the femoral shaft[11]are most common. **The Proximal Femoral Nail system[11](PFN)**, developed by AO/ASIF, has some major biomechanical innovations to overcome the previously mentioned limitations of the Gamma nail. In 2003, Christian Boldinet al[12] in his study concluded that Proximal Femoral Nail can be applied with a smaller incision with minimal tissue handling for unstable trochanteric fractures.

The **Proximal Femur Locking Compression Plate (PFLCP)** is a new weapon in the orthopaedic surgeon's armamentarium for the treatment of unstable trochanteric fractures. Yang YY et al[13], reported that functional recovery of PFLCP was better than DHS, and complications are fewer than that of DHS and other Intramedullary fixation devices in the management of unstable fractures.

From this, it is obvious that the ideal treatment for Unstable Intertrochanteric fractures remains controversial. Most of the currently available internal fixation devices can be expected to yield satisfactory results. However, each device has its own set of advantages and disadvantages.

In our study, an attempt was made to compare the various modalities of internal fixation for the treatment of unstable intertrochanteric fractures. The study was conducted on 42 patients at Rajah Muthiah Medical College Hospital between July 2013 and March 2014. The various modalities used were DHS (19 cases), PFN (12 cases), PFLCP (8 cases) and DCS (3 cases). The mean follow up period was 10.2 months (Range 6 – 14 months).

Age Distribution:

The average age incidence in our study was 56.21 years with 69 % of our patients falling in the age group of 51 – 70 years. This is in contrast to higher age groups as reported by western literatures. However, our study results are comparable with other Indian studies such as that of Mohanty SP et al[14].

Sex Distribution:

In our study, there were 22 Males and 20 Females showing a slight male preponderance. This is in contrast to female preponderance as observed by various other western authors[11,15]as the Indian males are more active and mobile than females.

Side of Involvement:

There was an equal distribution of fractures to the two sides in our study, with 21 patients suffering fracture on the right side and the remaining 21 patients suffering a left sided fracture in our study.

Case 2 – 50/M, Left side, Type 31A3.2

Pre OP

Immediate Post-OP | **6 weeks Post-OP**

3 months Post-OP | **6 months Post-OP**

Functional outcome at Six months

Case 3 – 67/M, Left side, Type 31A2.1

Pre-OP **Immediate-OP**

6 weeks Post-OP | **3 months Post-OP**

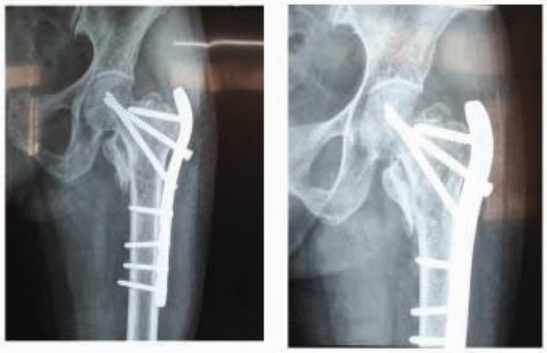

Functional outcome at Six months

Mode of Injury:

Commonest mode of injury was Road Traffic Accident with 22 cases (52.4%), followed by Self fall (Trivial fall) with 17 cases (40.5%) and Fall from height with 3 cases (7.1%). However, all the fractures that occurred in patients younger than 58 years were either due to Road traffic accident or Fall from height. This supports the view that bone stock plays an important role in the causation of fractures in the elderly, which occur after a trivial fall.

Fracture Classification:

Fractures were classified based on the AO/OTA classification with inclusion criteria being unstable fractures belonging to types 31A2 and 31A3. Majority of our patients (85.7%) had fractures falling under Type 31A2, with maximum number of patients (15) sustaining a Type 31A2.2 subgroup fracture (35.7%). Only 6 patients (14.3%) had a Type 31A3 fracture.

Method of Reduction:

In our study, in 31 patients (73.8%), we were able to achieve satisfactory reduction by closed means. Only 11 patients (26.2%) underwent open reduction out of which 8 patients underwent Iliopsoas tendon release.

Duration of Surgery:

The mean duration of surgery in our study was 70.48 minutes. This was comparable to other similar studies such as Dousaet al[11] whose mean operating time was 61 minutes. In 91.67% of patients who underwent PFN and 63.15% of patients who underwent DHS fixation, the duration of surgery was under 70 minutes, whereas in 62.5% of patients who underwent PFLCP and all 3 patients (100%) who underwent DCS fixation, the duration of surgery was over 70 minutes. The p value of 0.010 was found to be significant and hence it was inferred that, in our study, PFN and DHS fixation had significantly lower operating times when compared to PFLCP and DCS fixation.

Blood Loss:

The overall average blood loss was 290.48ml which was comparable with the mean blood loss of 282ml in the study conducted by Bellabarbaet al[16] in 2003. The least blood loss in our study was seen in patients undergoing DHS fixation with 94.74% having blood loss under 300ml, followed by PFN, where 83.33% patients had blood loss under 300ml. Among the patients who underwent PFLCP and DCS, the blood loss was significantly higher with a p value of 0.033.

Post Operative Complications:

Overall, only 7 out of 42 patients had complications in our series. 4 patients developed varus collapse, out of which 2 had undergone DHS and 1 each had undergone PFLCP and DCS fixation respectively. Superficial infection was noted in 2 cases of DHS and 1 case of PFN. The Chi-square test of significance was 0.623 and hence no significant association was observed between type of fixation and post operative complications. There were no incidences of Non union, Screw cut-out, Implant breakage or deep infection in our study.

Time for Radiological Fracture Union:

In our study, the overall mean time for radiological fracture union was 15.05 weeks, which was comparable to many other similar studies such as Ecker et al[17] (14 weeks) and Jensen et al[18] (16 weeks). The least time for union was seen with PFN (Mean 14.33 weeks). 66.67% of the patients who had undergone PFN had complete radiological union by 14 weeks followed by 50% of PFLCP and 47.37% of DHS patients who had complete union within the same period. The p value was significant at 0.040.

Functional Outcome:

The Functional outcome was assessed using the Modified Harris Hip Score. In our study, the overall mean Modified Harris Hip Score was 85.02. This was comparable with several other similar international studies such as those by Doskocil[19] and Butt[20]. Among the different groups, patients who had undergone PFN had the best functional outcome with a mean score of 88.25, with a significant p value of 0.015. This was followed by mean scores of 86.25 among the PFLCP group and 83 among the DHS group. The lowest mean score was 82, noted among the DCS group.

Overall, 9 patients (21.4%) had Excellent, 24 patients (57.1%) had Good and another 9 patients (21.4%) had Fair scores according to the Modified Harris Hip Scoring system. None of our patients had a Poor score.

5.CONCLUSION

The ideal modality of surgical management for unstable intertrochanteric fractures has remained a point of discussion with the advent of many new implants. However, it cannot be overemphasized that the key to a good outcome is to achieve a good fracture reduction, regardless of the method of stabilization.

Based on the results of our study, the **PFN** seems to have many distinct advantages over the remaining implants in terms of shorter operative times, relatively less blood loss and smaller incisions. In addition, the PFN had significantly better functional outcome, shorter time for complete radiological union and negligible post operative complications when compared with the other implants. It also has the unique advantages of closed reduction, preservation of fracture haematoma, less tissue damage, early post operative rehabilitation and weight bearing and early return to work.

The **DHS** had the least blood loss in our study and the operative times, time for fracture union and functional outcome were comparable to that of the PFN but there were also 2 cases of varus angulation with DHS. However, it may still be considered to be the implant of choice for stable intertrochanteric fractures.

The **PFLCP** took more operative time and had slightly higher blood loss in our hands but the functional outcome, time for union and complications were comparable to PFN. Hence, it may still be a valuable tool in the management of unstable intertrochanteric fractures with severe comminution or shattered lateral wall.

The **DCS** had the poorest results among all the implants. However, it may still have a role in the management of unstable intertrochanteric fractures, particularly the reverse obliquity type.

Finally, based on the above analysis, we conclude that the **PFN** is the implant of choice for the management of unstable intertrochanteric fractures and has proven to be a significant advancement in the management of such fractures with multiple advantages and an overall better outcome.

6.REFERENCES:

1. B.Tengre and J.Kjellander ; Antibiotic prophylaxis in operations on trochanteric femoral fractures ; Scand j prim health care sep 2002; 20(3);188-92.

2. Guimarães RP, Alves DP, Silva GB, Bittar ST, Ono NK, Honda E, et al. Tradução e adaptação transcultural do instrumento de avaliação do quadril "Harris Hip Score". ActaOrtop Bras. 2010;18(3):142-7.

3. M J Parker, C B Maheshwar. "The Use of Hip Scores in assessing the results of treatment of proximal femur fractures"; International orthopaedics,Springer.1997 Feb,21:262-264.

4. I. Saarenpää, T. Heikkinen, [...], and P. Jalovaara "Functional comparison of the dynamic hip screw and the Gamma locking nail in unstable trochanteric hip fractures: a matched-pair study of 268 patients"; IntOrthop. Feb 2009; 33 (1): 255 – 260.

5. George J. Haidukewych, T. Andrew Israel, Daniel J. Berry "Reverse Obliquity Fractures of the Intertrochanteric Region of the Femur"; The Journal of Bone & Joint SurgeryMay 2001,83(5)643-650.

6. Christophe Sadowski, Anne Lübbeke, Marc Saudan, Richard Stern, Pierre Hoffmeyer "Treatment of Reverse Oblique and Transverse Intertrochanteric Fractures with Use of an Intramedullary Nail or a 95° Screw-Plate"; The Journal of Bone & Joint SurgeryMar 2002,84(3)372-381;

7. Valverde JA, Alonso MG, Porro JG et al (1998) Use of Gamma nail in treatment of fractures of the proximal femur. ClinOrthop 350:56–61

8. Windoff J, Hollander DA, Hakimi M, Linhart W (2005) Pitfalls and complications in the use of proximal femoral nail. Langenbecks Arch Surg 390(1):59–65, Feb Epub 2004 Apr 15

9. Schipper IB, Bresina S, Wahl D, Linke B, van Vugt AB, Schneider E, et al. Biomechanical evaluation of the proximal femoral nail.ClinOrthop Related Res. 2002;(405):277-86

10. Rosenblum SF, Zuckerman JD, Kummer FJ, Tam BS (1992) A biomechanical evaluation of Gamma Nail. J Bone JtSurg 74:352–357

11. Dousa P, et al. Osteosyntehsis of trochanteric fractures using PFN. ActaChirOrhtopTraumatolCech 2002;69(1):22-30.

12. Christian Boldin, Franz J Seibert, Florian Fankhauser, GeroifPeicha, Wolfgang Grechenig and Rudolf Szyszkowitz. "The proximal femoral nail (PFN) - a minimal invasive treatment of unstable proximal femoral fractures A prospective study of 55 patients with a follow-up of 15 months ActaOrthopScand 2003;74(1):53-58.

13. Comparative study of intertrochanteric fractures with proximal femur locking compression plate, Wang y, yang yy, yuzh, Li cq, Wu ys, Zhengxx ,Zhongguo Gu Shang 2011 May ; 24(5):370-3.

14. Mohanty SP, Chacko V. A comparative analysis of operative and non-operative management of trochanteric fractures.A study of 135 consecutive cases. Indian Ortho 1984 Jan;18(1):19-24.

15. Pajarinen J, Lindahl J, Savolainen V, Michelsson O, Hirvensalo E. Femoral shaft medialisation and neck-shaft angle in unstable pertrochanteric femoral fractures. IntOrthop 2004;28:347–53.

16. Carlo Bellabarba; DolfiHerscovici Jr.; William M. Ricci; Percutaneous treatment of peritrochanteric fractures using the gamma nail; Journal of Orthopaedic Trauma. 2003;17(8 SUPPL.):S38-S50.

17. Ecker ML, Joyce JJ III, Kohl EJ. The treatment of trochanteric hip fractures using a compression screw. J Bone Joint Surg (Am). 1975 Jan;57(l):23-7.

18. Jensen JS, Sonne-Holm S, Tondevold E. Unstable trochanteric fractures.A comparative analysis of four methods of internal fixation. ActaOrthop Scand. 1980 Dec;51(6):949-62.

19. Doskocil,J. and Nasezkusenosti, S. lecboupertrochanterickyehzlomeninpripouziti DHS [Our experiences with the treatment of pertrochanteric fractures with the use of DHS]. Urazovachirurgie 2002; 10.8.

20. Butt MS, Krikler SJ, Nafie S, Ali MS. Comparison of dynamic hip screw and gamma nail: a prospective randomized controlled trail. Injury 1995;26:615-8.

*****