

*Int. J. Modn. Res. Revs.*

*Volume 2, Issue 10, pp 387-391, October, 2014*

ISSN: 2347-8314

ORIGINAL ARTICLE

## FUNCTIONAL OUTCOME OF BIPOLAR HEMIARTHROPLASTY IN FRACTURE NECK OF FEMUR.

\*<sup>1</sup>Dr.RamKumar Ponraj, <sup>2</sup>Dr.Senthilnathan Arumugam and <sup>3</sup>Dr.Prabhakar Ramabadrans<sup>3</sup>

Department of Orthopaedics, Rajah Muthiah Medical College and Hospital, Annamalai University

*Article History: Received 5<sup>th</sup> September,2014, Accepted 6<sup>th</sup> October, 2014, Published 7<sup>th</sup> October,2014*

### ABSTRACT

**PURPOSE:**Femoral neck fractures occur most commonly in elderly females. They are uncommon in patients under 60 years of age.<sup>1-3</sup> We undertook this study to assess the functional outcome of cemented and un-cemented bipolar hemiarthroplasty in patients above 50 years of age with intracapsular neck of femur fractures, and to determine the factors affecting the outcome. **MATERIALS AND METHODS:**Thirty patients above 50 years of age, with the mean age of 64 years ( range 52-87) with intra-capsular fracture neck of femur operated between May 2012 to March 2014 were undertaken for the study. They were operated with either cemented or uncemented bipolar hemiarthroplasty. The clinical and radiological follow-up was done for a minimum period of 6 months. The fractures were classified based on Garden's classification for femoral neck fractures. The results were assessed using Harris hip evaluation – modified (HHE). The factors affecting the outcome of results were assessed based on age, associated co-morbidities and patient's general condition. **RESULTS:**Out of 30 patients, 19 were females and 11 were males (ratio 1.7:1) with an average age of s 64 years. 22 patients had associated co-morbidities like diabetes(DM), hypertension(HTN), coronary artery disease(CAD) and chronic kidney disease(CKD). After 6 months of follow-up using HHE, 17 had good results, 7 had excellent results, 4 had fair results and poor results were observed in 2 patients. The mean Harris hip score was 84.2. Patients aged 51-60 years had better results based on Harris hip score with F-ratio (25.919) and p value (0.001) showing significance in this age group. Ambulation was delayed in three patients; two due to overweight with associated co-morbidities and one due to generalized weakness. There was no stem subsidence, acetabular erosion, acetabular protrusion, or heterotopic ossification in any of the patients during the follow-up period. **CONCLUSION:**In our study, all the patients had satisfactory functional outcome. There was no significant difference in using cemented or un-cemented bipolar prosthesis. To conclude, bipolar prosthesis is a safe option in treating fracture neck of femur in the elderly with good recovery in-spite of having several co-morbidities.

**Keywords:** Bipolar hemiarthroplasty, neck of femur fracture,

### 1.INTRODUCTION

Femoral neck fractures occur most commonly in elderly females. They are uncommon in patients under the age of 60 years<sup>1-3</sup>. Most patients give a history of low energy fall as the cause of injury. In 2-3 % of cases there is no history of trauma and the injury may be pathologic or a stress fracture. In India an estimate of 4,40,000 hip fractures occurs each year, a number that is expected to be 1 million by 2050.

The treatment goals for femoral neck fractures are early return to a satisfactory functional status along with the minimization of mortality, morbidity and the need for re-operation<sup>1</sup>.

The surgical options for femoral neck fractures include: internal fixation (with cancellous screws), emiarthroplasty,

and total hip replacement. Hemiarthroplasty is considered the optimal treatment for elderly patients with displaced femoral neck fractures. Internal fixation has a high rate of non-union and is with inferior results compared to hemiarthroplasty.

.Gilberty & James Ennis Bateman in 1974, introduced bipolar hemiarthroplasty, which is a self articulating prosthesis. Advantage of bipolar prosthesis is that erosion and protrusion of acetabulum would be less because, there is an dual articulation between the inner head and shell & shell and acetabulum

The study was to evaluate the functional outcome of cemented and uncemented bipolar hemiarthroplasty in elderly patients with intracapsular femoral neck fractures, and determine the factors affecting the outcome.

\*Corresponding author Dr.RamKumar Ponraj, Department of Orthopaedics, Rajah Muthiah Medical College & Hospital, Annamalai University, Annamalainagar – 608 002, Tamilnadu, India

## 2.MATERIALS AND METHODS

Thirty patients above 50 years of age, with neck of femur fracture were operated with bipolar hemiarthroplasty from May 2012 to March 2014 with a minimum follow up of 6 months. Surgical options were based on the patient's general condition and pre-injury mobility status. All patients were operated through posterior (southern-moore) approach, post operatively all patients received antibiotics and venous thrombo-embolism prophylaxis as per protocol. Postoperatively, partial weight bearing was allowed on 4<sup>th</sup> day. The outcome of the patients was assessed and tabulated and the mean of the Harris hip score will depict the results. The significance was calculated using 'T' test and 'ANOVA' test.

## 3.RESULTS

Figure : 1 AGE (mean 64 Years)

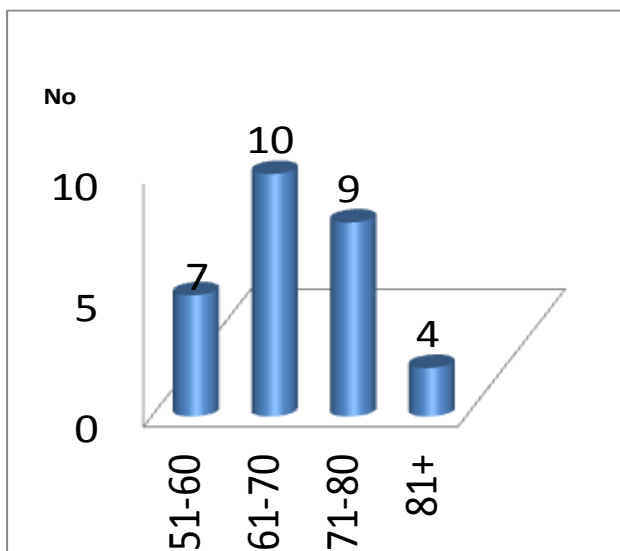


Figure : 2 co-morbidity

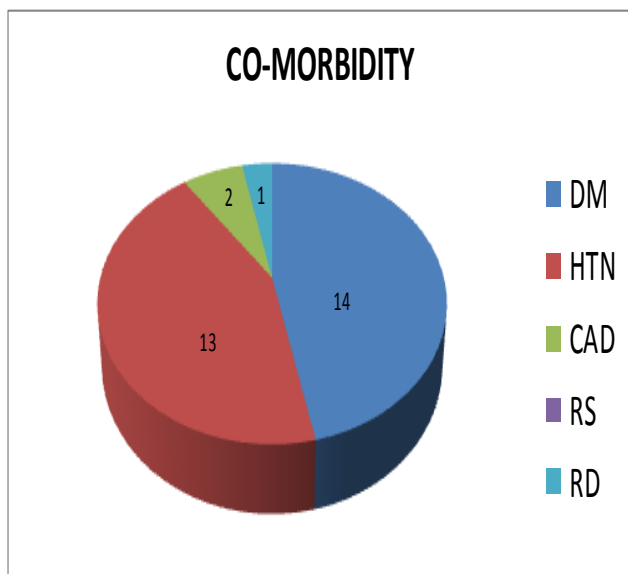


Figure 3 sex ratio 1.7:1

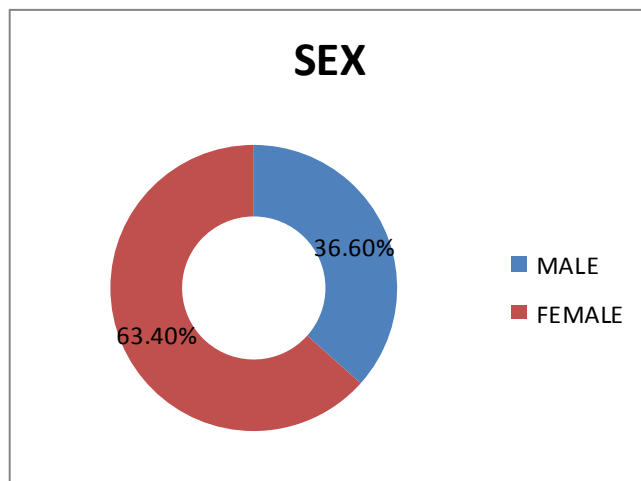
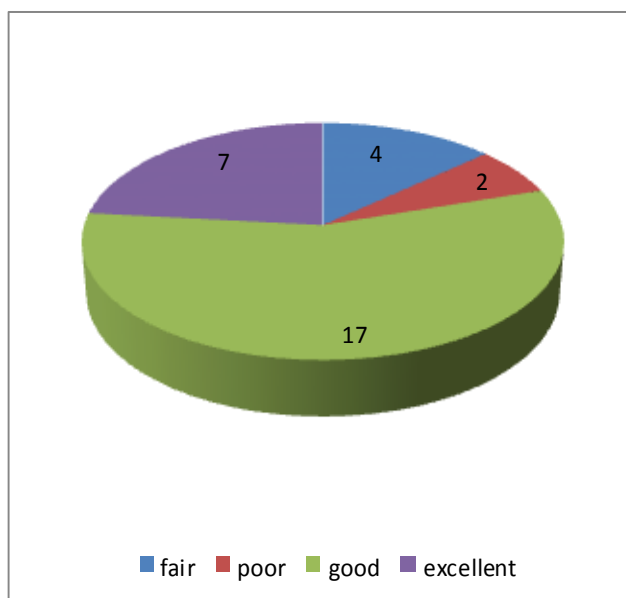


Figure: 4: HARRIS HIP SCORE



In the study of 30 patients with neck of femur fracture, the average age of the patients was 64 years. And the female-male ratio was 1.7:1. Out of 30 patients 22 patients had co-morbid conditions. 8 patients had DM alone, 7 had HTN alone, 4 had DM/HTN, 1 had HTN/CAD, 1 had DM/HTN/CAD and 1 had DM/HTN/CKD

The mean harris hip score for age, 51-60 years (93.14) scored higher than other age groups. The p value (<0.05), confirms that there is a significant difference in Harris hip score on the basis of age group. Based on t-test there was no significant difference in cemented and un-cemented bipolar prosthesis surgical outcomes (Table :2).

The average duration of surgery was 45 min (range, 30-60 min) with average blood loss of 260 ml (range, 95-535 ml). Average blood transfusion was 1.4 units including both preoperative and postoperative transfusions (range, 0 to 4 units). Mean duration of hospital stay was 11.9 days (7-26 days). We had no postoperative mortality or serious morbidity.

Table:1 Ttest for harris hip score.

Harriship Score	Poor	Fair	Good	Excellent	Total	Mean	SD	t-value	P Value
Cemented	2	1	8	3	14	3.50	3.11	0.577	0.604 (P>0.01)
Un-Cemented	0	3	9	4	16	4.00	3.74		

The above table shows the results of the 't' test carried out to compare the outcome of cemented and uncemented bipolar prosthesis with Harris hip score and it revealed that there is no significant difference between the outcomes of cemented and uncemented bipolar prosthesis in the study (t-value=0.577) P>0.01.

Two patients had lengthening (~1.0 cm). Ambulation was delayed in three patients, two were due to over weight and associated co-morbidities and one due to generalized weakness. The remaining 27 patients were discharged after rehabilitated walking with walker support. Partial to full weight-bearing was permitted only at 6 weeks. All of these patients achieved preinjury ambulatory status at 3 months. We had no instances of infection or dislocation in the immediate or late postoperative period.

We had a minimum follow-up of 6 months in all the thirty patients and few patients were followed up to 20 months. All were ambulatory and had painless hips. . At the follow up, 17 patients had good results, 7 patients had excellent results, 4 patients had fair results and 2 patients had poor results. The mean Harris hip score was 84.2 (range: 64–97).

There was no incidence of stem subsidence, acetabular erosion, acetabular protrusion, or heterotopic ossification in any of the patients during the follow up period.

Table: 2 ANOVA test for Harris hip Score Vs

Age	N	Mean harriship score	SD	F-value	P Value
51-60	7	93.14	4.25	25.919	0.001
61-70	10	85.70	3.80		
71-80	9	82.00	4.21		
81+	4	70.00	5.71		
<b>Total</b>	<b>30</b>	<b>84.23</b>	<b>8.12</b>		

In the table, the mean harris hip score for age, 51-60 years (93.14) scored higher value than other age groups. The calculated F-ratio (25.919), which is significant at 0.001 level, confirms that there is a significant difference in Harris hip score on the basis of age group.

CASE ILLUSTRATIONS

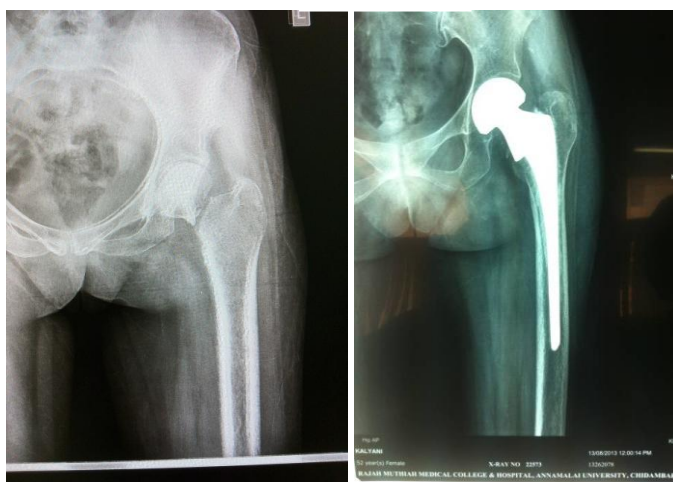
4.DISCUSSION

Elderly patients with fracture neck of femur who were mobile before injury, should be able to restore to their preoperative functional and ambulatory status.<sup>1-3</sup>

Results for femoral neck fracture treatment illustrated by Leighton *et al*<sup>3</sup> recommend prosthetic replacement for patients more than 60 years old having neck of femur fracture. Unipolar or bipolar (cemented) hemiarthroplasty has shown the most reliable and predictable outcomes. Uncemented stems are to be considered in patients with significant cardiovascular risk factors and who need total hip arthroplasty in the 'active elderly patient,' while unipolar prostheses (Moore or Thompson) are used only in minimally ambulatory patients<sup>3</sup>

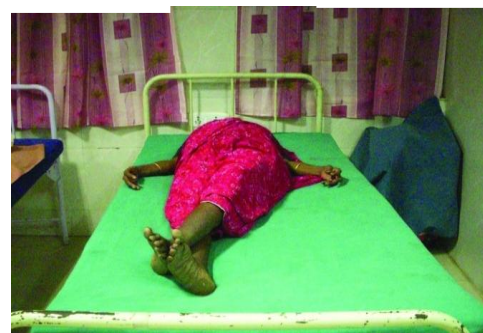A Cochrane database survey,<sup>1</sup> done with 17 trials involving 1920 patients, confirmed that, cemented bipolar hemiarthroplasty patients had minimal pain, better mobility, and no significant difference in complications when compared with un-cemented bipolar hemiarthroplasty patients. Similarly, no significant differences were found between unipolar and bipolar hemiarthroplasty (seven trials, 857 participants, 863 fractures) Parker MJ *et al*.<sup>1</sup> In our study, we found the results in comparison between cemented and uncemented bipolar prosthesis showed similar functional outcome.

CASE1

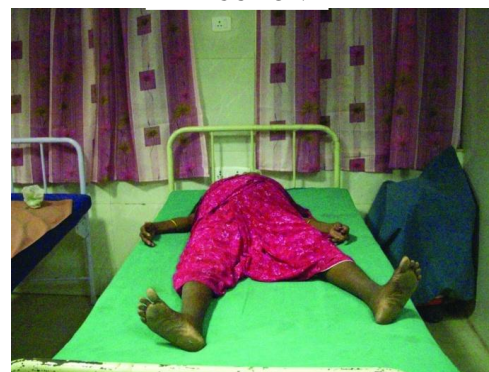

PRE-OP

POST-OP

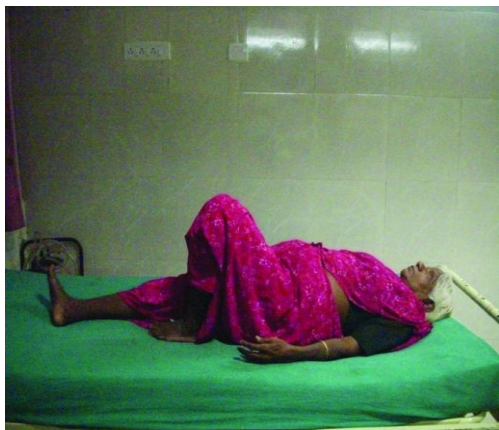

ADDUCTION



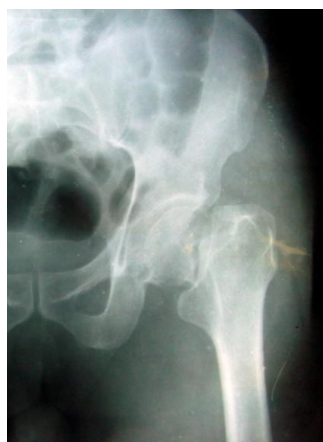ABDUCTION



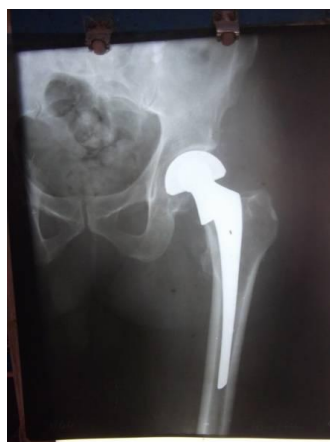

FL EXION

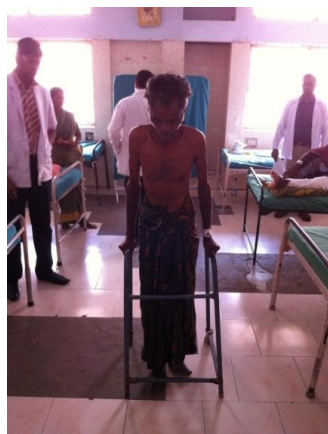CASE NO: 2



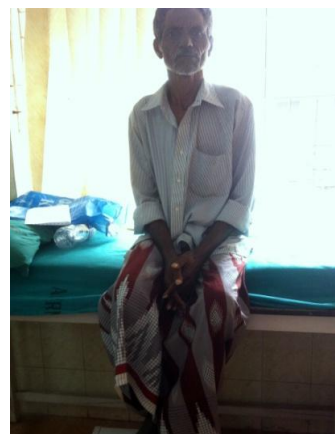PRE-OP



PRE-OP



PRE-OP



PRE-OP

4.DISCUSSIONS

Dorr *et al.*<sup>2</sup> also, in his prospective study of treatment of displaced neck of femur fractures with any of the femoral stem prosthesis, found no significant differences in pain, ambulation, or aids required. They advised against the use of un-cemented femoral stems in patients with wide canals (Dorr type C and D femurs) due to higher incidence of subsidence and loosening as a result of inadequate press-fit.<sup>2</sup>

When cemented and cementless prostheses were compared no significant differences were found in patients pain, walking distances, need of support, limp or sitting in high or normal chair. Lo *et al.* (14) found less thigh pain and higher Harris hip scores with patients treated with cemented prostheses. However in our study there was no significant evidence of any advantage and complications in cemented and Uncemented bipolar prosthesis.

Torisu<sup>4</sup> has reported the successful use of the bipolar implant without bone grafting in dysplastic osteo-arthritis in a series of 36 hips of the steep and shallow acetabulum. Survivorship analysis showed that 84.6 of the bipolar hip arthroplasties remained in place for 8 years. Torisu assessed the internal function of the bipolar, implant in 20 of 24 hip joints showing the implant having dominant function at the inner bearing.

At the Orthopaedic and Arthritic Hospital H.U. Cameron<sup>5</sup> has treated acetabular defects in some 37 cases using a bipolar implant. All cases have done well and no revisions have been required as long as 8 years post-operatively. There has been very minimal migration of the lead.

William . Murray *et al*<sup>6</sup> reserved the use of the bipolar device for the patients in whom contact between viable bone and prosthesis is less than 50 percent. Bone grafting was necessary in most of these patients.

Robertson and Debra Cohen<sup>7</sup> reported the use of a bipolar implant in failed total hip arthroplasty were the peri-acetabular bone loss precluded stable fixation with a conventional acetabular component. The functional results in this series were quite satisfactory.

Torisu<sup>4,8</sup> has reported the use of the bipolar implant in a series of 37 hips with significant acetabular deficiency. Measurement of possible migration was carried out and it was indicated that 5mm was the maximum change identified. At the end of 5 years there was no further migration of the head. In our study, due to minimal follow-up period, we were not able to report migration and acetabular erosion in any of our patients.

Wilson and R.D. Scott<sup>9</sup> reported successful use of bipolar implant in 47 cases for reconstruction of deficient acetabulum. They concluded that there was acceptable relief of pain and functional ability in these cases.

In Bateman<sup>10</sup> series, there were some 70 hips converted from ankylosis to mobility. The average pre-operative score was 45. The postoperative score was 82, with an average increment of 37. The use of a single assembly implant considerably facilitates this procedure.

Lestrange *et al*<sup>11</sup> has shown very successful results, using bipolar endoprosthesis in the treatment of unstable comminuted fractures, also. In 496 hip fractures reported by Lestrange, he concluded that the bipolar implant, cemented or uncemented, improves the results markedly. Primary arthroplasty has been especially useful in the treatment of unstable comminuted inter-trochanteric fractures, which occur in patients of more advanced age.

Colwill et al<sup>12</sup> concluded in their series of 88 cases in the elderly and debilitated that the overall results were gratifying.

In a series of 500 hips with displaced fractures of femoral neck reported by Garrahan and Madden<sup>13</sup> the use of long stem was recommended. They reported no evidence of acetabular erosion or protrusio acetabulae. The three-point fixation of the long stem remains secure within the femoral canal with a tendency to limit calcar stress.

Nottage and McMaster<sup>14</sup> concluded that bipolar prosthesis had significant advantages to fixed stem prosthesis for fractures and reconstruction of the hip. When cemented and cementless prostheses were compared no significant differences were found in patients pain, walking distances, need of support, limp or sitting in high or normal chair. Lo et al.<sup>15</sup> found less thigh pain and higher Harris hip scores with patients treated with cemented prostheses. However in our study there was no significant evidence of any advantage and complications in cemented and uncemented bipolar prosthesis.

## 5.CONCLUSION

In our study, all the patients had satisfactory functional outcome and all the patients resumed to their normal daily activity. There was no significant difference in using cemented and uncemented bipolar prosthesis. To conclude bipolar prosthesis is a safe option in treating fracture neck of femur in the elderly (above 50 years) with good recovery and pain free in spite of having several co morbidities. Usage of Uncemented bipolar also helps in easy revision to cemented total hip arthroplasty.

## 6.ACKNOWLEDGMENTS

I sincerely thank my co-authors Dr.Senthilnathan A, Dr.Prabhakar R and Dr.Krishna kumar A; for helping throughout the process of my studies and guiding me. We thank Mr. Arumugham for helping with statistics.

## 7.REFERENCES

1. Parker MJ, Gurusamy K. Arthroplasties (with and without bone cement) for proximal femoral fractures in adults. *Cochrane Database Syst Rev.* 2006;3:CD001706. [PubMed]
2. Dorr LD, Glousman R, Hoy AL, Vanis R, Chandler R. Treatment of femoral neck fractures

- with total hip replacement versus cemented and noncemented hemiarthroplasty. *J Arthroplasty.* 1986;1:21-8
3. Leighton RK, Schmidt AH, Collier P, Trask K. Advances in the treatment of intracapsular hip fractures in the elderly. *Injury.* 2007;38:S24-34.
4. Torisu T, Utsunomiya K, Maekawa M, Ueda Y. Use of bipolar hip arthroplasty in states of acetabular deficiency. *Clin Orthop.* 25:1: 119-125. 1990.
5. Cameron HU, Jung YB. Acetabular revision with a bipolar prosthesis. *Clin Orthop.* 251:100 - 103. 1990.
6. Murray WR. Acetabular salvage in revision total hip arthroplasty using the bipolar prosthesis. *Clin Orthop.* 259: 212 - 219. 1990.
7. Roberson JR, Cohen D. Bipolar components for severe periacetabular bone loss around the failed total hip arthroplasty. *Clin Orthop.* 251: 113-118. 1990.
8. Torisu T, Izumi H, Fujikawa Y, Matsui S. Bipolar hip arthroplasty without acetabular bone-grafting for dysplastic osteoarthritis. Results after 6-9 years. *J. Arthroplasty.* 10: (1) 15-27. 1995.
9. Wilson MG, Scott RD. Reconstruction of the deficient acetabulum using the bipolar socket. *Clin Orthop.* 251: 126 - 133. 1990.
10. Bateman JE, Berenji AR, Bayne O, Geyson ND. Long-term results of bipolar arthroplasty in osteoarthritis of the hip. *Clin Orthop.* 251:54-66, 1990.
11. Lestrang NR. Bipolar arthroplasty for 496 hip fractures. *Clin Orthop.* 251:7-19. 1990.
12. Labelle LW, Colwill JC, Swanson AB. Bateman bipolar hip arthroplasty for femoral neck fractures. A five - to ten year follow-up study. *Clin Orthop.* 251: 20-25. 1990.
13. Garrahan WF, Madden EJ. The long stem bipolar prosthesis in surgery of the hip. *Clin Orthop.* 251: 31 - 37. 1990.
14. Nottage WM, McMaster WC. Comparison of bipolar implants with fixed-neck prosthesis in femoral-neck fractures. *Clin Orthop.* 251:38-43. 1990.
15. Lo WH, Chen WM, Huang CK, Chen TH, Chiu FY, Chen CM: Bateman bipolar hemiarthroplasty for displaced intracapsular femoral neck fractures. Uncemented versus cemented. *Clin Orthop* 1994;302:75-82

\*\*\*\*\*