Available online at www.journalijmrr.com

INTERNATIONAL JOURNAL OF MODERN RESEARCH AND REVIEWS

ISSN: 2347-8314

Int. J. Modn. Res. Revs.
Volume 3, Issue 10, pp 855-860, October, 2015

ORIGINAL ARTICLE

HYSTEROSCOPY IN EVALUATION OF ABNORMAL UTERINE BLEEDING

[*1]Dr. Joeline Paulus, [2]Prof. Dr. Latha and [3]Dr. V.Jeyashree

[1*]Post Graduate, Department of Obstetrics and Gynaecology, Rajah Muthiah Medical College & Hospital, Annamalai University, Annamalai Nagar 608 002
[2]Professor, Department of Obstetrics and Gynaecology, Rajah Muthiah Medical College & Hospital, Annamalai University, Annamalai Nagar 608 002
[3]Reader, Department of Obstetrics and Gynaecology, Rajah Muthiah Medical College & Hospital, Annamalai University, Annamalai Nagar 608 002

Article History: *Received 4th October,2015, Accepted 18th October, 2015, Published 19th October,2015*

ABSTRACT

BACKGROUND: The objective of the study was to correlate hysteroscopic findings with histopathological findings in women with abnormal uterine bleeding and to study the accuracy of hysteroscopy in abnormal uterine bleeding. METHOD:A prospective study was carried out in the Department of Obstetrics and Gynaecology at RMMCH, Chidambaram from Jun 2013 to June 2015.50 cases were selected for this study from patients who were admitted with history of abnormal uterine bleeding. Hysteroscopic examination was done in all patients post-menstrually, whenever possible, except in those cases where menstrual cycles were grossly irregular or patients came with continuous bleeding per vaginum. The patients then underwent curettage and curettings was sent for histopathological examination. The correlation between findings on hysteroscopy and histopathological examination was done. RESULT: On hysteroscopy, 66% of the patients had either proliferative or secretory picture which was grouped as normal. The rest 34% of patients had some abnormality. The other findings included endometrial polyp 8%,submucous myoma 6%, atrophic endometrium 10%, endometrial carcinoma2%. CONCLUSION: Hysteroscopy has a high sensitivity i.e. it can supplement and enhance the accuracy of tissue diagnosis. So, hysteroscopically directed biopsy would be an ideal procedure in abnormal uterine bleeding wherever facilities are available.

Keywords: Abnormal uterine bleeding, Hysteroscopy,menorrhagia

1.INTRODUCTION

Abnormal Uterine Bleeding(AUB) is defined as any type of bleeding in which the duration, frequency, or amount is excessive for an individual patient.Abnormal uterine bleeding is responsible for more than one-third of gynecologic consultations and nearly two-thirds of hysterectomies(1,2).In addition to its inconvenience, AUB is regarded as a sign of possible uterine disease. Recent reports(3,4) demonstrate the distinct prognostic and management implications of benign, premalignant, and malignant causes.

A thorough history and physical examination are fundamental for the workup of AUB(5,6).Given that benign uterine diseases and endometrial hyperplasia are responsible for at least 70% of AUB cases, investigating the uterine cavity enables the gynecologist to offer the most appropriate therapy. Abnormal uterine bleeding in premenopausal and postmenopausal women is the single most common reason for gynaecological referrals. The most common diagnostic tests are hysteroscopy, sonohysterography, dilatation & curettage and ultrasonography.

Hysteroscopy permits direct visualization of the cervical canal and uterine cavity, enabling observation of intrauterine abnormalities. Over the past 30 years technical advances in instrumentation, optics and light sources have resulted in significant developments in diagnostic and operative endoscopy in the field of gynaecology. Diagnostic hysteroscopy, already described by Edstrom & Fernstrom in 1970, has been shown to be superior to conventional dilatation and curettage in evaluating abnormal uterine bleeding. Panoramic hysteroscopy allows a complete visual inspection of the uterine cavity, the endometrium and the endocervical canal, and tissue biopsy allows histological confirmation of the diagnosis(7).Advances in technology have enabled manufacturers of hysteroscopic equipment to significantly reduce the diameter of the instruments,

Corresponding author*: ***Dr. Joeline Paulus,* *Post Graduate, Department of Obstetrics and Gynaecology, Rajah Muthiah Medical College & Hospital, Annamalai University, Annamalai Nagar 608 002*

making diagnostic hysteroscopy without anaesthesia a genuine outpatient ambulatory procedure. The hysteroscopy combined with guided biopsy was more accurate than dilatation and curettage, and considered as 'gold standard' in uterine cavity evaluation. Hysteroscopy has emerged as a useful diagnostic procedure that is safe, with a low incidence of clinically significant complications .

Therefore, the purpose of our study was to correlate the diagnostic accuracy of hysteroscopy in women with symptoms of abnormal uterine bleeding with biopsy and emphasize the increasing use of outpatient hysteroscopy as an effective and acceptable method for treating patients with bleeding problems.

2.MATERIALS AND METHOD

This study was conducted in 50 women with abnormal uterine bleeding in department of obstetrics and gynaecology of Rajah Muthiah Medical College and Hospital, Chidambaram from June 2013 to June 2015.It is a prospective study.

Inclusion criteria:

1) Patients in reproductive and postmenopausal age group.
2) Patients with uterus normal to 12weeks size.
3) Patients without any medical complications

Exclusion criteria

1) Pregnant women, abortions, ectopic pregnancy
2) Patients who have uterine and cervical infections, PID
3) Pateints who have STDs and vaginitis.
4) Lower genital tract malignancies.
5) Medical contraindications to any invasive procedures.

The gynaecological history and history of any past medical illnesses of the patient is taken. The bladder is emptied and uterine size is clinically assessed .Routine blood investigations & Trans abdominal sonography done. Consent for doing hysteroscopy is obtained

PROCEDURE

Hysteroscopies will be performed under i.v sedation (in the midproliferative phase of the menstrual cycle for premenopausal women) using a Wolf 3 mm hysteroscope. The patients bladder was emptied before the procedure.Patient was put in lithotomy position and bimanual pelvic examination done.A speculum was inserted into the vagina and anterior lip of cervix is grasped.Endocervical curettage was done.During the procedure, sometimes we may also dilate the cervix to aid in allowing the hysteroscope into the uterus.

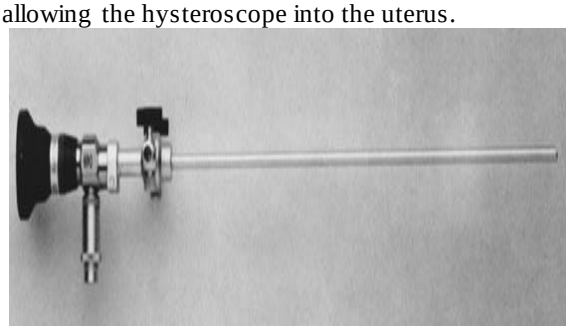

Fig.1.Wolf 3mm hysteroscope

The uterine cavity was distended with normal saline which was infused by pneumatic cuff under manometric control at a pressure of 100–150 mmHg at a flow rate of 0-70ml/min.

All the procedures were monitored and recorded with the use of an endoscopic video camera with projection to a monitor. The examination of uterine cavity was done in a systematic manner.Hysteroscope was guided through the endocervical canal into the uterine cavity under visual control.Tubal ostia were identified and endometrial surfaces of anterior,posterior and lateral walls visualised for appearance, colour of endometrium,or presence of any pathological findings.Suspicious areas were marked for curettage and endometrial curettage done.

Procedure was defined as

- Complete - complete examination of entire uterine cavity including both ostia
- Incomplete - examination of entire uterine cavity not possible eg.lesions
- Failed - examination of uterine cavity not possible

3.RESULTS

TABLE 1 AGE DISTRIBUTION

AGE(IN YEARS)	NO OF PATIENTS	PERCENTAGE
22-32	7	14
33-42	18	36
43-52	20	40
>52	5	10
TOTAL	50	100

AGE(IN YEARS)	MEAN	STANDARD DEVIATION
AGE	41.70	8.66

The age distribution of the study women is presented in table 1. It is inferred that, 43 – 52 years is the common age where 40% of the women are observed. The next common age is 33 – 42 years in which 36% of the women are observed.

The mean age of the women is 41.70 $\pm$ 8.66 years

TABLE 2 PARITY STATUS

PARITY	NO OF PATIENTS	PERCENTAGE
NULLIPAROUS	10	20
MULTIPAROUS	40	80
TOTAL	50	100

In table 2, parity status of the women is presented. It is inferred that, majority of women are multiparous (80%).

TABLE 3PRESENTATION OF COMPLAINTS

COMPLAINTS	NO OF PATIENTS	PERCENTAGE
MENORRHAGIA	39	78
METRORRHAGIA	3	6
POSTMENOPAUSAL BLEEDING	8	16
TOTAL	50	100

The presentation of complaints is analysed in table 3. It is inferred that, the more common presentation of problem is menorrhagia where 78% of patients are getting affected. The next common presentation is post menopausal in which 16% of patients are observed. The least common presentation is metrorrhagia where only 6% of patients are observed.

TABLE 4 DURATION OF COMPLAINTS

DURATION OF COMPLAINTS	NO OF PATIENTS	PERCENTAGE
<6 MONTHS	11	22
6-12 MONTHS	30	60
>6 MONTHS	9	18
TOTAL	50	100

The duration of complaints is presented in table 4. It is observed that, majority of patients (60%) are presented with the symptoms for 6 to 12 months. The duration of complaints is less than 6 months for 22% of women. For 18% of women, the symptoms lasting more than 12 months.

TABLE 5 MENOPAUSE ATTAINED

MENOPAUSE ATTAINED	NO OF PATIENTS	PERCENTAGE
YES	8	16
NO	42	84
TOTAL	50	100

From table 5 it is observed that majority of women (84%) have not attained menopause. 16% of study women have attained menopause.

TABLE 6 HYSTEROSCOPIC FINDINGS

HYSTEROSCOPIC FINDINGS	NO OF PATIENTS	PERCENTAGE
PROLIFERATIVE ENDOMETRIUM	28	56
SECRETORY ENDOMETRIUM	5	10
ENDOMETRIAL HYPERPLASIA	4	8
ENDOMETRIAL POLYP	4	8
SUBMUCOUS FIBROID	3	6
ENDOMETRIAL ATROPHY	5	10
ENDOMETRIAL CARCINOMA	1	2
TOTAL	50	100

In table 6, the details of hysteroscopic findings is presented. Proliferative endometrium is the more common findings (56%) followed by secretory endometrium (10%). 8% of women are presented with endometrial hyperplasia and again for 8% of women, the feature is endometrial polyp. Submucous fibroid is observed for 6% and only 2% has endometrial carcin

TABLE 7 HISTOPATHOLOGICAL FINDINGS

HISTOPATHOLOGICAL FINDINGS	NO OF PATIENTS	PERCENTAGE
PROLIFERATIVE ENDOMETRIUM	31	62
SECRETORY ENDOMETRIUM	5	10
SIMPLE HYPERPLASIA WITHOUT ATYPIA	3	6
COMPLEX HYPERPLASIA WITHOUT ATYPIA	1	2
SIMPLE HYPERPLASIA WITH ATYPIA	1	2
SUBMUCOUS FIBROID	3	6
ENDOMETRIAL ATROPHY	5	10
ENDOMETRIAL CARCINOMA	1	2
TOTAL	50	100

The histopathological findings is presented in table 7. It is observed that, 62% are presented with proliferative endometrium and which is the common findings. For 10% each secretory endometrium and endometrial atrophy is the observed findings. Simple hyperplasia without atypia is the feature for 6% of women. Submucous fibroid is observed for 6% of women. Complex hyperplasia without atypia, simplehyperplasia with atypia and endometrial carcinoma are observed for each of 2% of women.

TABLE 8 ASSOCIATION OF HISTOPATHOLOGICAL FINDINGS Vs HYSTEROSCOPIC FINDINGS

	HYSTEROSCOPIC FINDINGS							
HISTOPATHOLOGICAL FINDINGS	**PROLIFERATIVE ENDOMETRIUM**	**SECRETORY ENDOMETRIUM**	**ENDOMETRIAL HYPERPLASIA**	**ENDOMETRIAL POLY**	**SUBMUCOUS FIBROID**	**ENDOMETRIAL ATROPHY**	**ENDOMETRIAL CARCINOMA**	**TOTAL**
PROLIFERATIVE ENDOMETRIUM	27	0	0	4	0	0	0	31
SECRETORY ENDOMETRIUM	0	5	0	0	0	0	0	5
SIMPLE HYPERPLASIA WITHOUT ATYPIA	0	0	3	0	0	0	0	3
COMPLEX HYPERPLASIA WITHOUT ATYPIA	0	0	1	0	0	0	0	1
SIMPLE HYPERPLASIA WITH ATYPIA	1	0	0	0	0	0	0	1
SUBMUCOUS FIBROID	0	0	0	0	3	0	0	3
ENDOMETRIAL ATROPHY	0	0	0	0	0	5	0	5
ENDOMETRIAL CARCINOMA	0	0	0	0	0	0	1	1
TOTAL	28	5	4	4	3	5	1	50

CHI SQUARE TEST

	VALUE	LEVEL OF SIGNIFICANCE
PEARSON'S CHI SQUARE	228.36	0.001

One patient who showed proliferative pattern in the hysteroscopy had histopathological feature of simple hyperplasia with atypia..

Table 8 represents, association of histopathological finding with hysteroscopic findings. Pearsons chi-square value is 228.36 with the corresponding P value of .001 which is lesser than .05 and hence significant association observed.

Therefore the findings of hysteroscopic study and histopathological study are significantly associated with each other.

4.DISCUSSION

Abnormal uterine bleeding is one the most frequently encountered conditions in gynecology. As quoted by Devi and Menon, the incidence is 30-40% of all gynecological cases.

In this prospective study, 50 women between 22 and 60 years of age who presented with complaints of abnormal uterine bleeding pattern had undergone two modalities of investigations to reach a conclusion - diagnostic hysteroscopy and endometrial histpathology report.

This study was undertaken to correlate the hysteroscopic findings with histopathologic report.

Patients with proliferative endometrium

In 28(56%) patients, endometrium was pink, smooth and thin, appearing to be of proliferative type. The same was confirmed by histopathology in 27 patients. Histology of the endometrial curetting revealed proliferative endometrium with tall columnar cells and pseudostratification. Findings were different in 1 case which showed simplehyperplasia with atypia. Sensitivity, specificity, positive predictive value and negative predictive value of hysteroscopy for proliferative endometrium compared to histopathology were 96.43%, 81.82%, 87.0% and 94.7%, respectively.

Fig.2 Hysteroscopic finding of proliferative endometrium

Patients with secretory endometrium

Hysteroscopy proved uterine cavity to be normal with orange, undulating and thick endometrium appearing to be secretory endometrium in 5(10%) cases. It was confirmed in 5 cases. Diagnostic accuracy of hysteroscopy for secretory endometrium was 100%. So, sensitivity, specificity, positive predictive value and negative predictive value of hysteroscopy for secretory endometrium were 100%, 100%, 100%, and 100%, respectively.

Panda *et al(8),* had reported diagnostic accuracy for normal endometrium as 92.5%.

Fig 3. Hysteroscopic finding of secretory endometrium

Patients with hyperplastic endometrium

In these patients, the endometrium appeared to be thickened, edematous and undulating. There were 4(8%) patients with this hysteroscopic finding. This finding was consistent with histology of the endometrium in 4 cases. Three cases had simple hyperplasia without atypia; one had complex hyperplasia without atypia.

Sensitivity, specificity, positive predictive value and negative predictive value of hysteroscopy for hyperplasia were 100%, 100%, 100% and 100%, respectively.

Loverro *et al.,(9)* stated the sensitivity, specificity, positive predictive value and negative predictive value as 98, 95, 63 and 99%, respectively, for endometrial hyperplasia.

Arslan *et al.,* did hysteroscopy in 216 premenopausal and 114 postmenopausal women for diagnosing hyperplasia. The positive predictive value was 71.4% and negative predictive value was 95.4% in diagnosis.

Fig.4 Hysteroscopic finding of endometrial hyperplasia

Submucous myoma

A white-colored bulge, round in shape, with a smooth surface, which was diagnosed on hysteroscopy as submucous leiomyoma, was found in 3(6%) patients. All 3 case was confirmed on histopathology.

Diagnostic accuracy of hysteroscopy was 100%. So, sensitivity, specificity, positive predictive value and negative predictive value of hysteroscopy for fibroid compared with histopathology were 100, 100, 100 and 100%, respectively.

Similar findings were reported by Panda(8) and Veena. But Veena and Sheth had reported 88 and 81%, respectively, of diagnostic accuracy.

Patients with endometrial polyp

In 4(8%) patients on hysteroscopy, small growths in the uterine cavity, which were soft, oval, pedunculated with a smooth surface were seen. These growths appeared as endometrial polyps. Histopathology report confirmed the findings in five cases. It showed proliferative endometrium.

Diagnostic accuracy of hysteroscopy for endometrial polyp was 62% when compared to histopathology. But considering

the final diagnosis, diagnostic accuracy was 100%. So, sensitivity, specificity, positive predictive value and negative predictive value of hysteroscopy for endometrial polyp compared to histopathology were 100, 100, 100 and 100%, respectively.

Haller *et al.*, had reported sensitivity and specificity of 100 and 96.7%, respectively. Anuradha Panda[s] had reported diagnostic accuracy of 100% in diagnosing polyp. Acharya Veena had obtained sensitivity, specificity, positive predictive value and negative predictive value of hysteroscopy for endometrial polyp as 100% each. But Valle and Seth had obtained a diagnostic accuracy of 88.6 and 81.8%, respectively.

Atrophic endometrium

In 5(10%) patients, the endometrium appeared flat, thin and fragile. At some points; petechie and hemorrhages were present. The tubal ostia were very prominent. The picture was suggestive of atrophic endometrium, which was also confirmed by histopathology in five cases.

Diagnostic accuracy of hysteroscopy was *100%*. So, sensitivity, specificity, positive predictive value and negative predictive value of hysteroscopy for atrophic endometrium were 100, 100, 100 and 100%, respectively.

This correlated with the report of Panda *et* al., Haller *et al.*, had reported sensitivity and specificity of 100 and 97%, respectively.

Carcinoma endometrium

In 1(2%) patients, hyperplasia, with polypoidal growth, with areas of ulceration, hemorrhage and increased vascularity were labeled as carcinoma endometrium on hysteroscopy. One case was confirmed on histopathology.

Diagnostic accuracy of hysteroscopy was 100%. So, sensitivity, specificity, positive predictive value and negative predictive value of hysteroscopy for carcinoma endometrium were 100, 100, 100 and 100%, respectively.

Mencaglia(10) combined hysteroscopy with endometrial biopsy for diagnosing endometrial carcinoma and found nearly 100% accuracy in the diagnosis of endometrial neoplasia and its precursors. But Haller *et al.*, had got a reduced sensitivity of 50% but better specificity of 100%. Valle(11) and Panda had obtained diagnostic accuracy of 100% each. Hysteroscopy revealed a sensitivity, specificity, positive predictive value and negative predictive value of 100, 49.6, 81 and 100%, respectively.

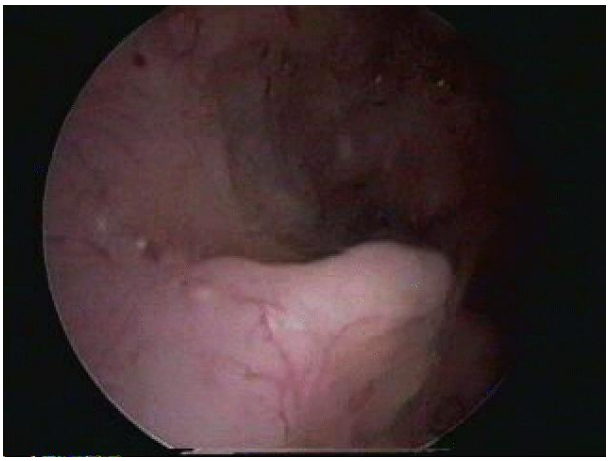

Fig 5. Hysteroscopic finding of endometrial carcinoma

So, to conclude, hysteroscopy was more accurate (100%) in identifying intrauterine pathologies like endometrial hyperplasia,endometrial atrophy, endometrial polyp, submucous myoma than endometrial biopsy or dilatation and curettage alone. Sensitivity – 96.43% for proliferative endometrium and it is 100% for other findings. Specificity – 81.82% for proliferative endometirum and 100% for other detections Histopathology had 100% accuracy in diagnosing proliferative endometrium..

5.CONCLUSION

Hysteroscopy is a valuable, simple, low risk technique which allows an adequate exploration of uterine cavity under visual control.It ensures speed and safety with diagnosis and treatment.The results are immediately available and prompt and effective treatment is possible.This makes hysteroscopy an accurate diagnostic tool in evaluation of abnormal uterine bleeding.

6.REFERENCES

1. Emanuel MH, Verdel MJC, Stas H,Wamsteker K, Lammes FB. An audit of true prevalence of intra-uterine pathology: the hysteroscopical findings controlled for patient selection in 1202 patients with abnormal uterine bleeding. Gynaecol Endosc 1995;4:237–41.
2. Van Dongen H, de Kroon C, Jacobi C, Trimbos B, Jansen F. Diagnostic hysteroscopy in abnormal uterine bleeding: a systematic review and meta-analysis. BJOG 2007;114:664–675.
3. Goldstein RB, Bree RL, Benson CB, Benacerraf BR, Bloss JD, Carlos R,et al. Evaluation of the woman with postmenopausal bleeding: Society of Radiologists in Ultrasound-Sponsored Consensus Conference statement. J Ultrasound Med 2001;20:1025 36.
4. Clark TJ, Voit D, Gupta JK, Hyde C, Song F, Khan KS.Accuracy of hysteroscopy in the diagnosis of endometrial cancer and hyperplasia: systematic quantitative review. JAMA 2002;288:1610–21.
5. Farquhar C, Ekeroma A, Furness S, Arroll B. A systematic review of transvaginal ultrasonography, sonohysterography and hysteroscopy for the investigation of abnormal uterine bleeding in premenopausal women. Acta Obstet Gynecol Scand 2003;82:493–504.
6. Olav Istre Erik Qvigstad. Current treatment options for abnormal uterine bleeding: an evidence-based approach. Best Practice & Research Clinical Obstetrics and Gynaecology Vol.21, No. 6, pp. 905–913, 2007
7. Gimpelson RJ, Rappold HO. A comparative study between panoramic hysteroscopy with directed biopsies and dilatation and curettage. A review of 276 cases. Am J Obstet Gynecol 1988;158:489–92.

Panda A, Parulekar SV, Gupta A. Diagnostic hysteroscopy in abnormal uterine bleeding and its histopathological correlation. J Obstet Gynaecol India. 1999;175:74-6.

8. Loverro G, Bettocchi S, Cormio G, Nicolardi V, Porreca MR, Pansini N et al. Diagnostic accuracy of hysteroscopy in endometrial hyperplasia. Maturitas. 1996;25(3):187-91.
9. Mencaglia L, Pernio A, Hamou J. Hysteroscopy in peri-menopausal and postmenopausal women with abnormal uterine bleeding. J Reprod Med. 1987;32(8):577-82.
10. Velle RF. Hysteroscopic evaluation of patients with abnormal uterine bleeding. Surg Gynaecol Obstet. 1981;153(4):521-6.

*****